

# Cardiac MRI—a Unique Perspective for Myocardial Tissue Characterization

Today, clinicians have a wide variety of imaging tools that are used to non-invasively assess coronary heart disease (CHD)—nuclear medicine, echo ultrasound, CT, and MRI. Each offers some benefit and, in many instances, these diagnostic imaging studies are used to complement and correlate findings. Cardiac magnetic resonance (CMR) provides a unique perspective on myocardial tissue characteristics, which is important for diagnosis and management of patients with CHD.

According to Jonathan W. Weinsaft, MD, Assistant Professor of Medicine (Cardiology), Associate Professor of Medicine in Radiology, Weill Medical College of Cornell University, CMR offers important diagnostic information concerning a wide variety of medical conditions that affect the heart.

Cardiomyopathy is one of the major indications of CMR and has received the “Appropriate” category in the 2006 American Heart Association appropriateness guideline for CMR.<sup>1</sup> These include both ischemic cardiomyopathies, due to coronary artery disease and sequelae such as myocardial infarction, as well as multiple non-ischemic cardiomyopathies, such as myocardial sarcoid, hypertrophic cardiomyopathy and cardiac amyloidosis (Table 1).

Table 1

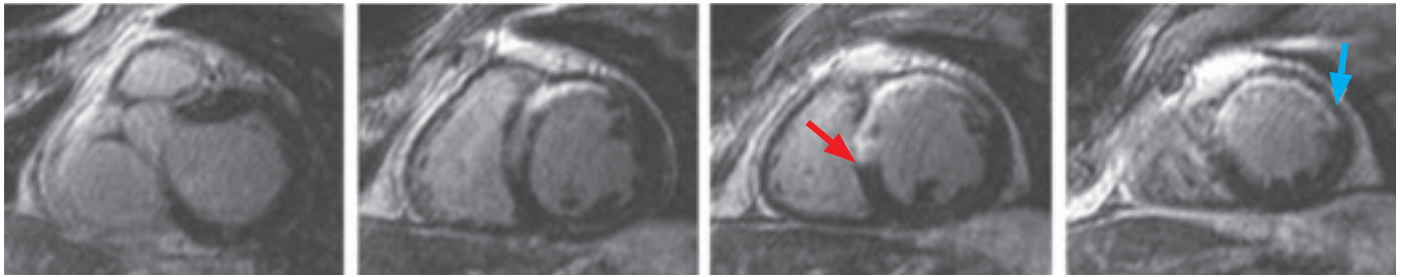
Myocardial sarcoid, or sarcoidosis, is a multisystem granulomatous inflammatory disease of unknown cause. If many granulomas form in an organ, they can affect how the organ works. Although less common in the heart, it can lead to serious complications.

Hypertrophic cardiomyopathy (HCM) is a condition in which the heart muscle becomes thick. The thickening makes it harder for blood to leave the heart, forcing the heart to work harder to pump blood.

Cardiac amyloidosis is a disorder caused by deposits of an abnormal protein (amyloid) in the heart tissue, which make it hard for the heart to work properly.

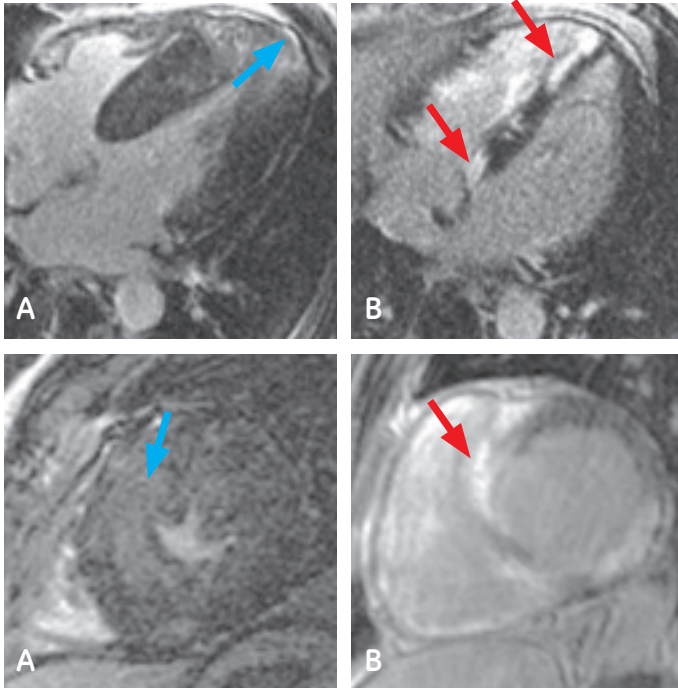
Source: National Institutes of Health

### Ischemic Cardiomyopathy



**Figure 1.** Typical example of CMR for assessment of myocardial infarction in a patient with an ischemic cardiomyopathy. In this case, CMR demonstrates a myocardial infarction involving the mid-distal anterior wall and anteroseptum. Note that CMR is able to distinguish regions of transmural (red arrow) and subendocardial (blue arrow) myocardial infarction. This capability of CMR—assessment of transmural extent of infarction—can assist in predicting the response to revascularization and medical therapy.

### Non-Ischemic Cardiomyopathy



**Figure 2.** Typical examples of non-ischemic signal intensity patterns as shown by CMR. (A) Hypertrophic cardiomyopathy, characterized by patchy signal intensity involving the septum and LV apex (blue arrows). (B) Myocardial sarcoid, characterized by focal signal involving the epicardial and mid myocardial aspects of the septum as well as focal transmural lesion involving the basal lateral wall (red arrows). [Long axis-4 chamber images top row, short axis images bottom row.]

### CMR for ischemic cardiomyopathy

For patients with cardiac dysfunction due to CAD, “CMR can help assess both presence and transmural extent of myocardial infarction so as to determine whether heart muscle is dead or alive,” Dr. Weinsaft explains. “CMR is often used for non-invasive assessment of the presence and transmural extent of myocardial infarctions. Whereas transmural myocardial infarctions will not respond to revascularization, dysfunctional but viable myocardium can respond to both medical and interventional therapies, resulting in improvement in myocardial contractility and clinical outcomes.”

He continues, “CMR provides unique insight regarding tissue characterization and changes in the heart muscle, particularly myocardial substrate within the left ventricle. This information is not only important in the diagnosis of CAD, but also for the clinical management of patients with myocardial dysfunction irrespective of whether CAD is present or absent.”

Quite simply, he says, it is the muscle that matters when determining treatment plans. “Of critical importance to clinicians is whether or not the heart muscle will respond to treatment.”

### CMR for non-ischemic cardiomyopathy

For patients with cardiac dysfunction in the absence of CAD, CMR also provides critical diagnostic information. According to Dr. Weinsaft, myocardial tissue abnormalities as identified by CMR can be used to diagnose conditions such as cardiac amyloid, hypertrophic cardiomyopathy, iron overload, myocarditis, and a wide variety of other conditions that cannot be identified by assessment of coronary anatomy or myocardial contractility.

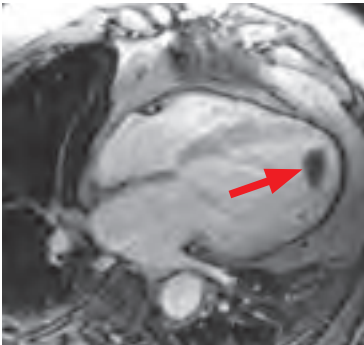


Figure 3. Left ventricular apical thrombus.

“CMR provides unique insight regarding tissue characterization and changes in the heart muscle, particularly myocardial substrate within the left ventricle.”

*Dr. Jonathan Weinsaft*

### CMR for cardiac thrombus detection

Dr. Weinsaft also sees great potential for CMR in managing other sequelae of CHD, such as cardiac thrombus. Traditional thrombus detection has relied on echocardiography, which identifies thrombus based on anatomic appearance/shape. While this approach is straightforward when thrombus is large or protuberant, it can be challenging when thrombi are small or flat. Says Dr. Weinsaft, “Whereas thrombus can vary in size or shape, it can be inherently defined based on avascular tissue characteristics, which can be demonstrated on CMR.”

In a study published in 2009 with Dr. Weinsaft as lead author, CMR provided nearly a two-fold improvement in identification of LV thrombus compared to echocardiography.<sup>1</sup> Another study by Dr. Weinsaft’s research group found that patients with left ventricular thrombus detected by CMR had a greater risk for clinical thrombo-embolic events or thrombectomy than did patients without thrombus.<sup>2</sup> Taken together, these findings demonstrate the clinical importance of left ventricular thrombus detection by CMR.

### Building a CMR practice

Advancements in MR technology, including pulse sequence advancements and the growing clinical availability of 3T MR, have increased the clinical utility of this exciting modality. According to Dr. Weinsaft, “Image quality is markedly improved; add to that better, faster pulse sequences and parallel imaging techniques that are easier to implement.” The continued development of cardiac sequences, such as T2 weighted imaging that helps in the assessment of infarct age, T1 mapping for assisting in the diagnosis of myocardial inflammation, better Time Course, mapping of 4D flow, and free breathing imaging sequences, along with the commercialization of MR-compatible pacemakers/implantable devices, will continue to expand clinical use and raise the importance of CMR.

Based on his clinical and research experiences, Dr. Weinsaft sees CMR as a “very powerful imaging tool that can help guide therapeutic treatment and predict clinical outcomes for patients with a wide variety of cardiac conditions.”

Advances in CMR have resulted in continued growth for Dr. Weinsaft’s program, which currently performs approximately 100 dedicated CMR studies per month.



"We've learned that educating the referring physician is the key," he explains, "and that includes enabling them to see and assess the images online." Then, he says, they will understand the power of the technology and how CMR can help them guide patient management.

Another key to success is tailoring the exam to the clinical question. He advises, "There are so many things we can do with CMR—so be sure that you understand the question and how to best answer it" before the patient enters the magnet.

A final word of advice from Dr. Weinsaft is for the healthcare provider to offer a wide variety of imaging protocols that can be employed to answer the pertinent clinical question. "Our program offers dedicated protocols for ischemic assessment, infarct imaging, valve characterization, and assessment of non-ischemic cardiomyopathies," he says. "Each protocol can be tailored to comprehensively address the clinical question within a well-structured and efficient exam time."

According to Dr. Weinsaft, "We have only scratched the surface of CMR's capabilities." ■

#### References:

1. Weinsaft JW, Kim RJ, Ross M, et al. Contrast-Enhanced Anatomic Imaging as Compared to Contrast-Enhanced Tissue Characterization for Detection of Left Ventricular Thrombus. *J Am Coll Cardiol, Cardiovascular Imaging* 2009; 2(8): 969-979.
2. Weinsaft JW, Kim, HW, Shah, DJ, et al. Detection of Left Ventricular Thrombus by Delayed-Enhancement Cardiovascular Magnetic Resonance. *J Am Coll Cardiol*, 2008; 52: 148-157.



*Dr. Jonathan Weinsaft*

Jonathan Weinsaft, MD, is Associate Professor of Medicine (Cardiology) and Medicine in Radiology at Weill Medical College of Cornell University, where he directs the cardiac MRI program. He completed undergraduate and graduate studies at New York University and subsequently received his medical degree from the New York University School of Medicine. Dr. Weinsaft completed his Internal Medicine residency and Cardiology fellowship at the New York Presbyterian Hospital Weill Cornell Medical Center, and a research fellowship in cardiovascular imaging at Duke University Medical Center. In addition to serving as the Michael J. Wolk Foundation Clinical Scholar at NYP—Cornell (2005), Dr. Weinsaft has received the American Heart Association's Laennec Society Young Clinician Award (2001), the American Society of Nuclear Cardiology Young Investigator Award (2003), and the Doris Duke Charitable Foundation Clinical Scientist Development Award (2006). Research interests include use of cardiac MRI for identification of ischemic and infarcted myocardium, as well as prognostic risk assessment.

#### About the facility

New York-Presbyterian Hospital/Weill Cornell Medical Center, located in New York City, is one of the leading academic medical centers in the world, comprising the teaching hospital (New York-Presbyterian) and Weill Cornell Medical College (the medical school of Cornell University).

New York-Presbyterian Hospital brings together renowned expertise in all areas of cardiovascular medicine from both New York-Presbyterian Hospital/Columbia University Medical Center and New York-Presbyterian Hospital/Weill Cornell Medical Center to provide the best patient care and services. In 2009–2010, the program was ranked 7th in the nation in the annual America's Best Hospitals survey conducted by U.S. News and World Report. The hospital offers a full range of state-of-the-art diagnostic services, including intracoronary ultrasound, cardiac catheterization, electrophysiologic studies, cardiac MRI, PET, SPECT, and MUGA scans.

## Tips to building a successful CMR practice:

1. Educate the referring physician—allow him or her to see and assess the images online.
2. Interface directly with the referring physician.
3. Examine the patient population and referral base. Can CMR answer the key clinical questions in your community?
4. Train techs to be comfortable with the exam, including the software and system speed when using parallel imaging.
5. Tailor the exam to answer the clinical question.